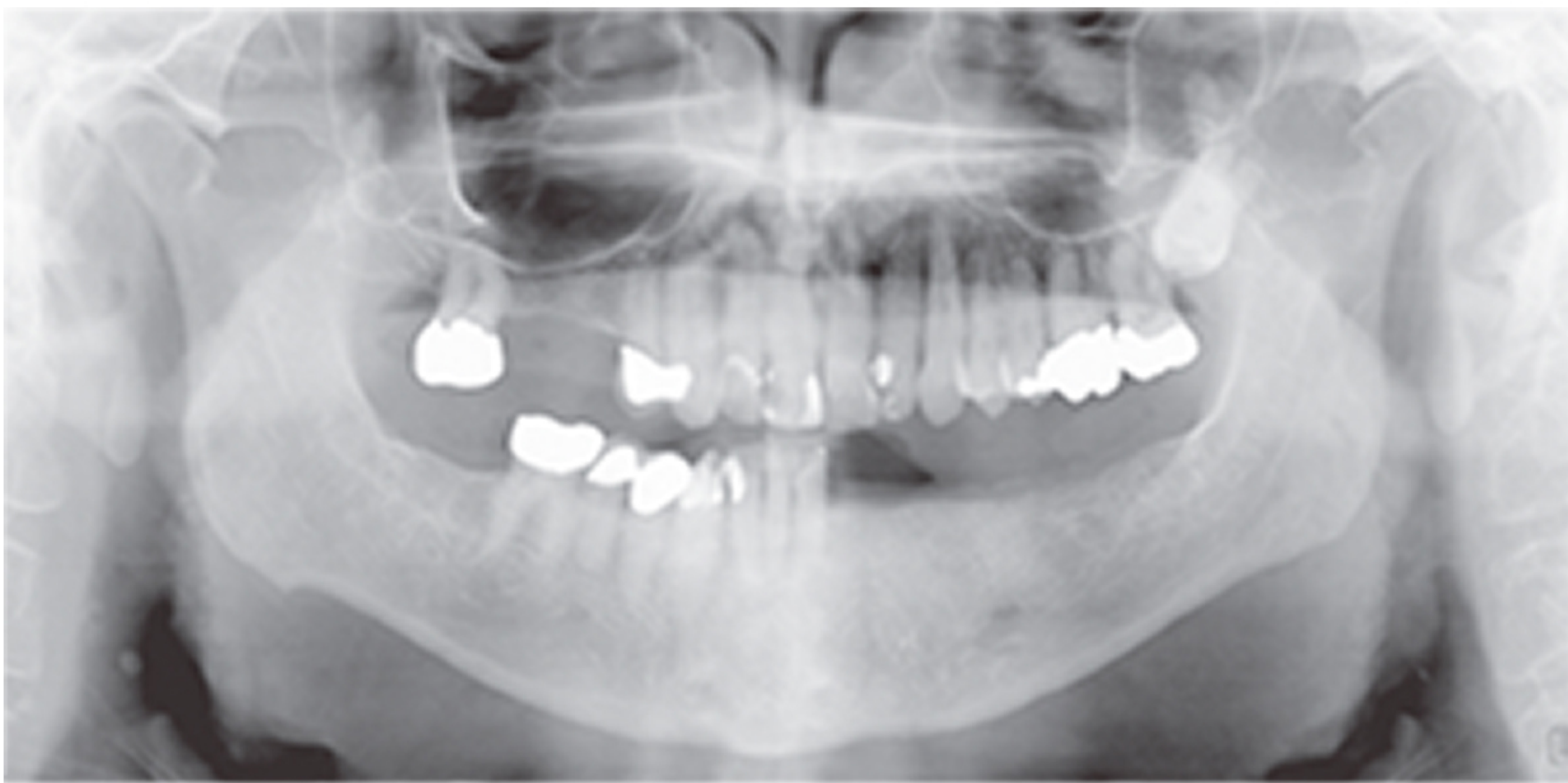
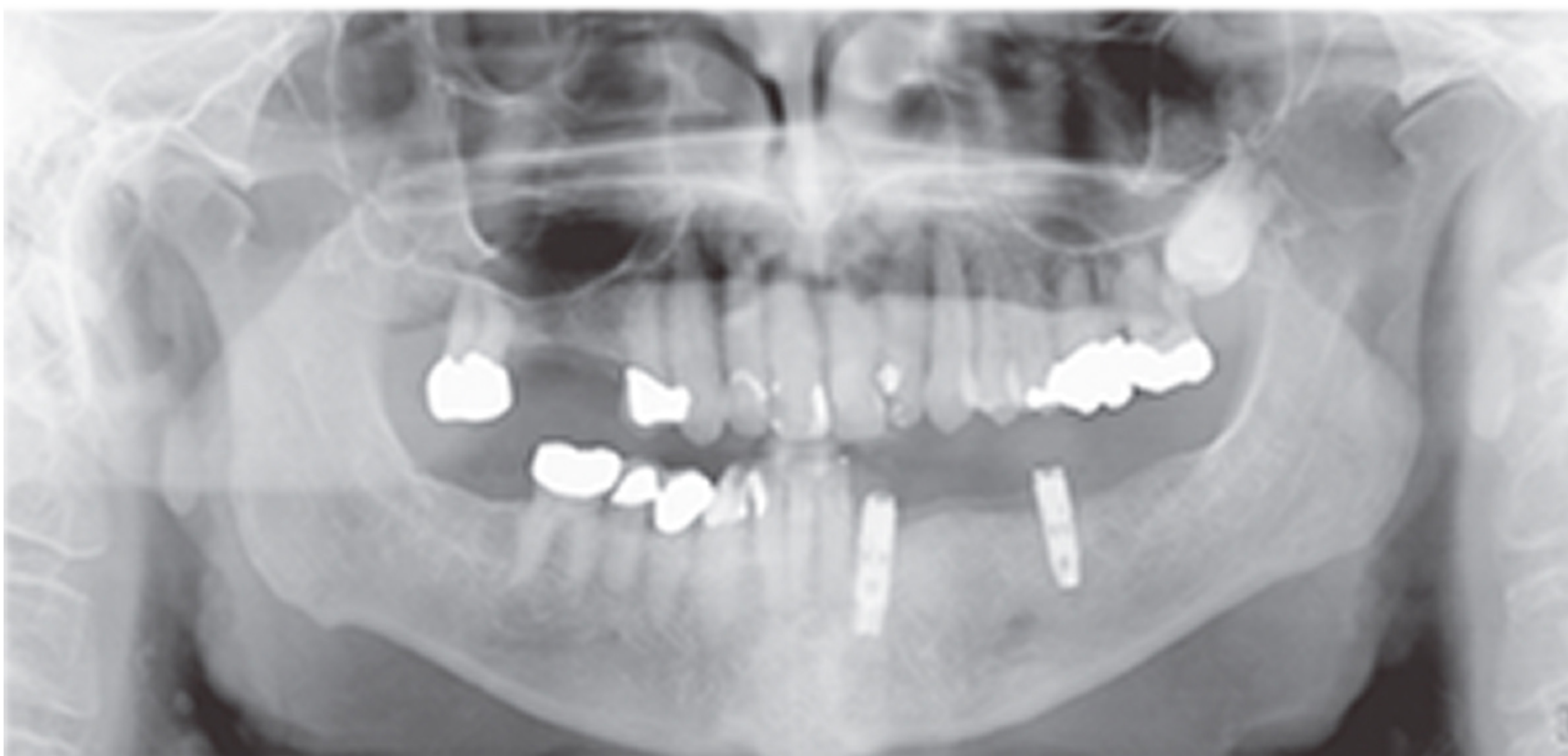



Implant-supported Mandibular Removable Partial Denture



Presurgical radiograph showing missing lower left teeth that were replaced by a removable partial denture. Patient complained that the partial denture moved up/down during chewing and caused significant discomfort.



The removable partial denture is now supported on the left side by the two implants with Locator[®] abutments and the right side is still supported by attaching to the teeth. This makes the removable partial denture more comfortable to wear, chew more effectively, and holding it down helps keep from getting food lodged under it.

